

Pulmonary Hypertension and the Vevo[®]

Overview:

The objective of this application note is to review what pulmonary hypertension is and how the Vevo high frequency ultrasound systems can be used to perform the necessary measurements and calculations to monitor pathological progression in small animal models of this disease.

Introduction:

Pulmonary hypertension is a disease in which there is an increase in blood pressure in the pulmonary vasculature. This increase may occur in the pulmonary artery, vein or capillaries. The etiology of the disease is varied and often presents with symptoms exacerbated by exertion, including shortness of breath, fainting as well as dizziness.

Pulmonary arterial hypertension, the most common of the four types of diseases, involves the constriction of blood vessels which conduct the blood from the heart to the lungs or constriction of the vessels within the lungs. This places increased pressure on the right side of the heart to try to pump blood through the pulmonary vasculature and remodeling occurs. The right ventricle undergoes hypertrophy and there is a build of fibrotic tissue in the affected vessels which leads to thickening and stiffening of the vessel wall.

Echocardiography is a non-invasive real-time technique in which cardiac function as well as hemodynamics can be assessed. In the case of pulmonary arterial hypertension the right side of the heart proves exceedingly important, including the flow through the pulmonary artery and vein, as well as the tricuspid valve. The right ventricular diameter as well as wall thickness is also important in prognosis of the disease. Characterization of left ventricle function as well as flow through the mitral valve is also beneficial in this disease, as in advanced pathology there is some diastolic dysfunction as well as effects on cardiac function.

The Vevo High-Frequency Ultrasound Systems have been developed specifically for use in small animal imaging and are ideally suited for mouse or rat echocardiography. With center operating frequencies ranging from 15MHz to 50MHz one imaging system can be used to assess cardiac function from embryo to adult in many commonly used small animal models.

Utility of the Vevo in Pulmonary Hypertension Research:

The majority of echocardiography literature on pulmonary hypertension pertains to research done on human patients. However there are numerous transgenic and chemically induced mouse models of pulmonary arterial hypertension¹. The same type of measurements and calculations performed on human patients to monitor disease could also be applied to mouse models to follow the progression or regression of disease throughout the course of a longitudinal study. Preliminary work done with the Vevo[®] elegantly demonstrates the imaging planes and measurements possible in mouse echocardiography². While review articles on pulmonary hypertension outline the key measurements and subsequent calculations which have proved useful in the clinic³. Echocardiography is considered the first-line diagnostic test, from which subsequent imaging or interventions can be recommended.

Below are the key measurements which can be performed using the Vevo High-Frequency Ultrasound System to investigate pulmonary hypertension models:

- **Right Ventricle**
- **Tricuspid Valve**
- **Right Ventricular Outflow Tract**
- **Pulmonary Vein**
- **Mitral Valve**
- **Left Ventricle**

Right Ventricle

Due to increased pressures in the right ventricle this chamber of the heart is often enlarged and the walls thickened. B-Mode parasternal long axis view of the right ventricle can be used to visualize the chamber and M-Mode analysis can be used to measure the ventricle diameter as well as the thickness of the right ventricular anterior wall.

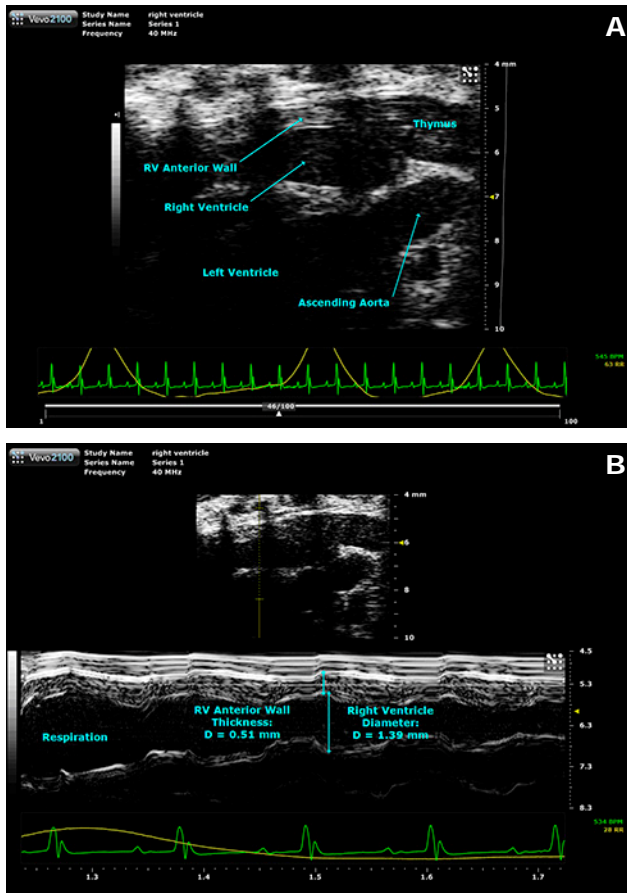


Figure 1 – B-mode imaging is used to identify the right ventricle including the anterior wall (A). M-mode imaging allows for accurate measurement of the ventricle diameter and anterior wall thickness in diastole (B).

Tricuspid Valve

Flow through the tricuspid valve is also affected in pulmonary hypertension due to the increased pressure in the ventricle, as disease progression regurgitation through the valve is often present. Color Doppler can be used to identify flow through the valve in an apical four chamber view, while Pulsed Wave Doppler can be used to quantify the blood flow spectrum. The E and the A peaks can be quantified, but of most importance to pulmonary hypertension is the peak tricuspid regurgitation

velocity (TRV), as it is involved in the calculation of pulmonary vascular resistance (PVR). The images shown below are from a normal mouse and therefore do not show regurgitation. If present it would appear as a strong spike downwards in the spectrum having significant velocity. PVR is used clinically to manage patients with cardiovascular and pulmonary diseases. Calculating this variable used to require catheterization. However a reliable non-invasive technique has been developed using measurements easily acquired using echocardiography⁴. The additional measurement required for this calculation is the velocity time interval from the right ventricular outflow tract, which will be covered in the next section.

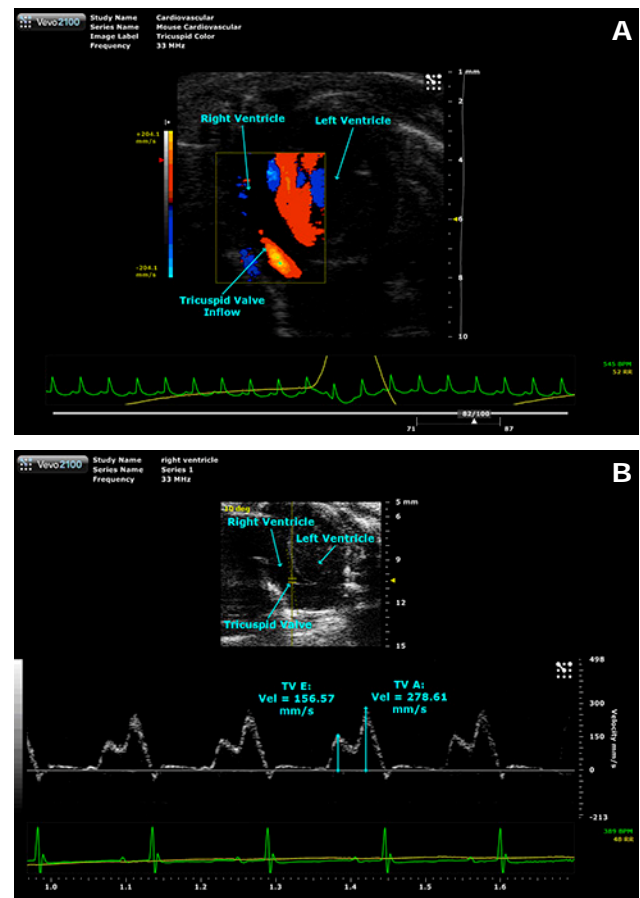


Figure 2 – Color Doppler is used to identify the tricuspid valve (TV) inflow (A), while Pulsed Wave Doppler is used to quantify the velocities of the early (E) and atrial (A) (B). This spectrum is from a normal mouse so no tricuspid regurgitation velocity (TRV) was visible. However the velocity of this flow could be measured in a similar manner as the E and A peaks and would be included in the pulmonary vascular resistance (PVR) calculation.

Right Ventricular Outflow Tract

The pulmonary valve is easily visualized from a modified parasternal long axis view of the left ventricle where the probe is shifted up the thoracic cavity of the mouse. Pulsed Wave Doppler reveals a strong spectrum on which the velocity time interval (VTI) is easily traced. The VTI_{RVOT} along with the TRV (measured above) can be used to calculate the PVR in Wood's Units using the following equation³:

$$PVR(WU) = 10 \times TRV/VTI_{RVOT}$$

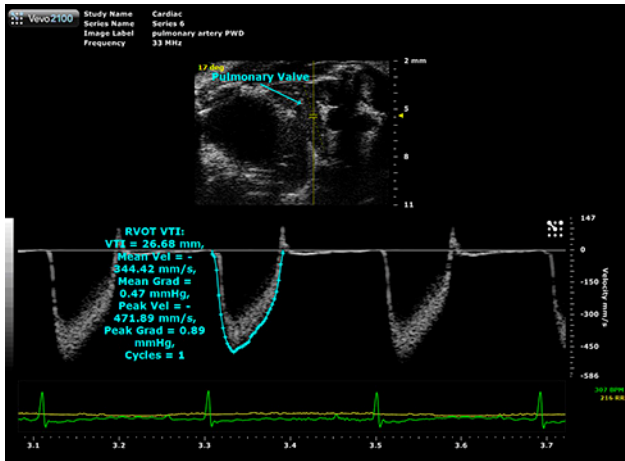


Figure 3 – Pulsed Wave Doppler on the right ventricular outflow (RVOT) where the velocity time interval (VTI) is measured for inclusion in the pulmonary vascular resistance (PVR) calculation.

Pulmonary Vein

Return flow from the lungs to the hearts may also be affected by pulmonary hypertension so interrogation of the pulmonary veins is also important. Again Color Doppler can be used to visualize the flow from a modified parasternal long axis view of the left ventricle in which the left atrium is visible, while Pulsed Wave Doppler is used to quantify the blood flow spectrum showing the diastolic, systolic and atrial peaks. As the disease progresses return of blood to the heart may decrease and these changes would be visible from this type of imaging.

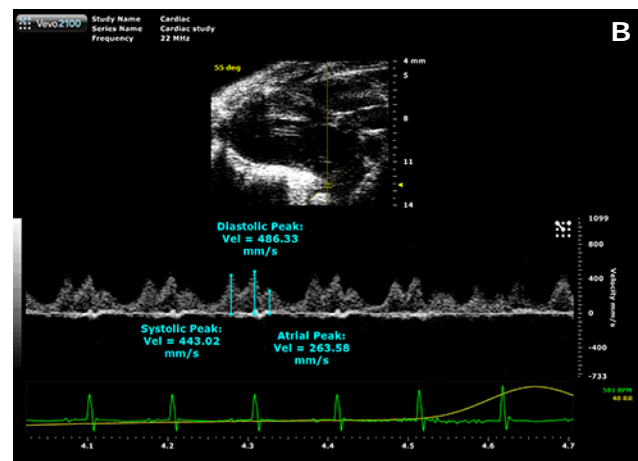
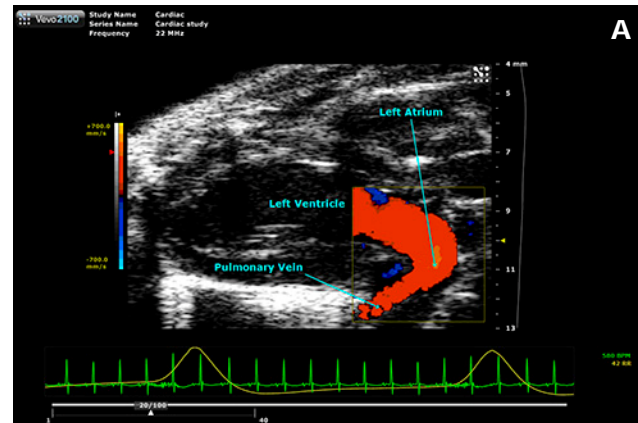


Figure 4 – Color Doppler is used to identify the pulmonary veins (A), while Pulsed Wave Doppler is used to quantify the velocities of various peaks in the spectrum (B), including the systolic, diastolic and atrial peaks.

Mitral Valve

Diastolic dysfunction can occur in later stages of pulmonary hypertension. This can be assessed using Pulsed Wave Doppler on the mitral valve from a modified apical four chamber view. There are numerous measurements made on this blood flow spectrum including the E and A peak velocities as well as the isovolumic relaxation and contraction times (IVRT and IVCT), which along with the aortic ejection time (AET) are used to calculate the myocardial performance index (MPI).

$$MPI = (IVRT + IVCT)/AET$$

Application Note: Pulmonary Hypertension and the Vevo

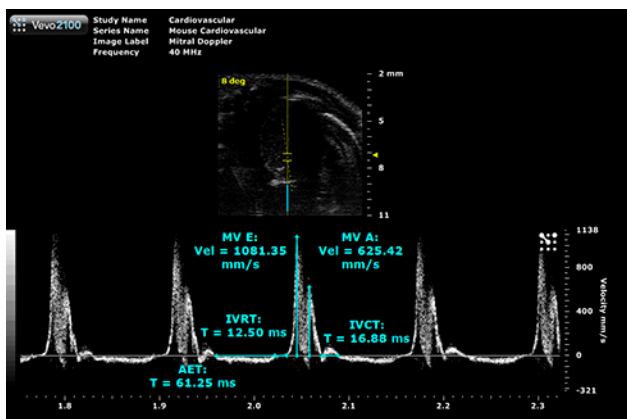


Figure 5 – Pulsed Wave Doppler is used to assess flow through the mitral valve. Here the peak velocities of the early (E) and atrial (A) peaks are measured, along with the isovolumic relaxation and contraction times (IVRT and IVCT) and the aortic ejection time (AET). The latter three measurements are used in the myocardial performance index.

Left Ventricle

In addition to the dramatic changes seen on the right side of the heart, there may also be changes to the left side of the heart which can be assessed from either a parasternal long or short axis view. There are various measurements and calculations which can be used to assess cardiac function in the left ventricle, both from B-mode and M-mode images. Here examples from a modified Simpson’s type measurement are used to assess cardiac function as well as LV mass. Measures of cardiac function include stroke volume, ejection fraction, fractional shortening, fractional area change, cardiac output. Additionally, the LV mass and average wall thickness is also calculated.

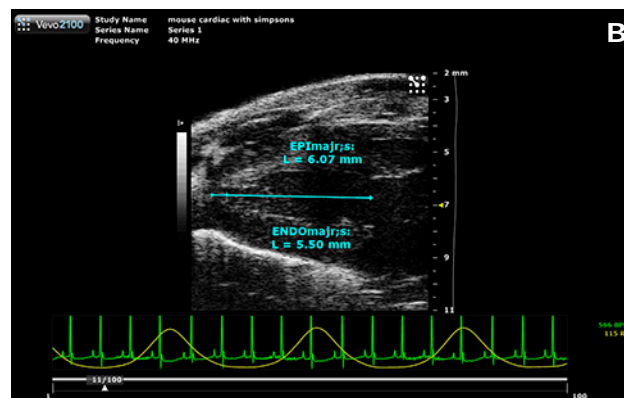
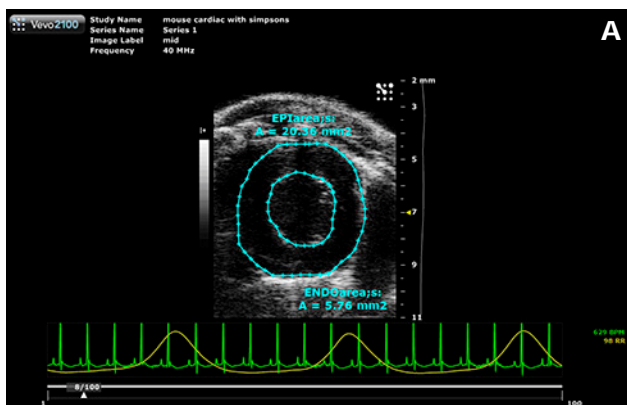


Figure 6 – B-Mode imaging can be used to assess cardiac function. Epicardial and endocardial areas are traced in both systole and diastole from a short axis view (A), while the endocardial and epicardial lengths are measured again in both systole and diastole from a long axis view (B).

Conclusion:

The Vevo High-Frequency Ultrasound Systems are well suited for a complete echocardiography exam in which the key measurements and calculations can be completed to fully assess pulmonary arterial hypertension models. Due to the non-invasive nature of ultrasound imaging, repeated exams would be possible on the same mouse over the course of a longitudinal study to either study the progression or regression of disease, adding to the strength of the acquired data and reducing the number of animals required to complete a powerful study.

References:

1. Summer, R., C.A. Fiack, Y. Ikeda, K. Sato, et al. 2009.
Adiponectin Deficiency: a Model of Pulmonary Hypertension Associated with Pulmonary Vascular Disease.
AM J Physiol Lung Cell Mol Physiol. Sept; 297(3): L432-8.
2. Zhou, Y.Q., S. Foster, B.J. Nieman, L. Davidson, et al. 2004.
Comprehensive Transthoracic Cardiac Imaging in Mice Using Ultrasound Biomicroscopy with Anatomical Confirmation by Magnetic Resonance Imaging.
Physiol Genomics. 18:232-244.
3. Bossone, E., B.D. Bordini, A. Mazza, L. Allegra. 2005.
Pulmonary Arterial Hypertension: The Key Role of Echocardiography.
Chest. May; 125(5): 1836-43.
4. Abbas, A.E., F.D. Fortuin, N.B. Schiller, C.P. Appleton, et al. 2003.
A Simple Method for Noninvasive Estimation of Pulmonary Vascular Resistance.
J Am Coll Cardiology. 41:1021-1027.



VISUALSONICS

VisualSonics Inc.

T.1.416.484.5000

Toll Free (North America) 1.866.416.4636

Toll Free (Europe) +800.0751.2020

E. info@visualsonics.com

www.visualsonics.com

VisualSonics®, Vevo®, MicroMarker™, VevoStrain™, DEPO®, SoniGene™, RMV™, EKV® and Insight through In Vivo Imaging™ are trademarks of VisualSonics Inc.